
CASE REPORT**Intramedullary Dermoid Cyst- A Rare Case Report***Aditi Gujarathi^{1*}, Abhijit Patil¹, Naware S. S.¹, Kulkarni Vilas M.¹**¹Dept of Radio-diagnosis, Dr. D. Y. Patil Medical College, Hospital and Research Centre, Pimpri, Pune - (Maharashtra) India.***Abstract:**

A 35 years old male came with complaints of low back ache radiating to right lower limb and is associated with tingling numbness and thin stream of urine since 1 year. Radiograph lumbo-sacral spine came out to be normal and thus MRI lumbo-sacral spine was done which revealed an intramedullary spinal tumour. Subsequent CT scan was done for the patient. Considering the tumour characteristics, diagnosis of intramedullary dermoid was made.

Keywords: Dermoid Cyst, Intramedullary Lesions, Spinal Tumours

Introduction:

Dermoids are benign inclusion tumours rarely presenting in adults. Typically they present in children in the region of the conus medullaris and are generally extramedullary. We present a very rare case of intramedullary dermoid cyst, presenting in a middle aged patient causing progressive neuro-deficit. Our case is rare as dermoids tumours constitute only for 1 – 2 % of intraspinal tumours [1].

Case History:

A 35 years old male came with complaints of low back ache radiating to right lower limb which was associated with tingling numbness and thin stream of urine since 1 year. It was not associated with weakness. There was no history of trauma. No history of any previous operative procedure.

On clinical examination, the skin over the neck and back was normal with no evidence of any sinus, hairy patch, or any cutaneous mark. Power in right lower limb was 4/5 and left was 5/5. Reflexes were normal. Radiograph of lumbo-sacral spine was done which was normal.

For further evaluation, MR imaging examination of lumbo-sacral spine with screening of whole spine was performed with a 1.5 T unit (Magnetom Avanto, Siemens, Munich, Germany). The conus appeared inconspicuous with a large lobulated long segment intramedullary solid – cystic lesion extending from L2 to S2 vertebrae. It measured approximately 13.8 cm (supero-inferior) x 1.94 cm (transverse). It was causing significant widening of spinal canal without any scalloping of the vertebrae. The upper one third of the lesion was hyperintense on T1 (Fig. 1 & 4) and T2 (Fig. 2 & 5) weighted images and showed loss of signal in fat suppressed images (Fig. 3) suggestive of fatty component. The middle one third and lower third were predominantly cystic, with the middle one third appearing hyperintense on T2WI (Fig. 2) and hypointense on T1WI (Fig. 1). Ill-defined hyperintensities on T1WI (Fig. 1) images which appeared hypointense on T2WI (Fig. 2) and STIR (Fig. 3) as well as on GRE in the lower one third suggestive of hemorrhage within the cystic portion.

There were well defined foci of blooming on GRE in the spinal canal at the level of S1-2 vertebrae suggestive of calcifications. A well defined focal fat signal was also seen at L5 level, probably in the intradural compartment. Spina bifida was seen at L5 level.

There was no evidence of any obvious sinus tract or herniation of meninges or soft tissue abnormality in this region. MRI brain with whole spine screening was also done which was normal.

Limited plain CT scan was performed on GE duo FII scanner. The foci of blooming within the lesion which were seen on GRE images of MRI

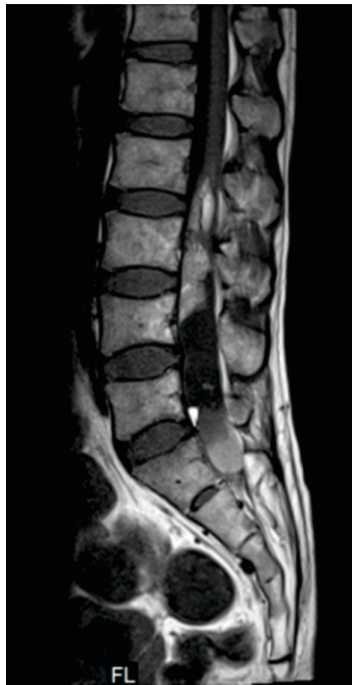


Fig. 1: T1 Mid Sagittal MR Image of the Lumbar Spine Showing Fat in the Solid Component Appearing as Well Defined Hyperintensity in the Upper One Third, Cystic Area Appearing Hypointense in the Middle One Third and Hemorrhage within the Cystic Component Appearing as Ill-Defined Hyperintense Signal

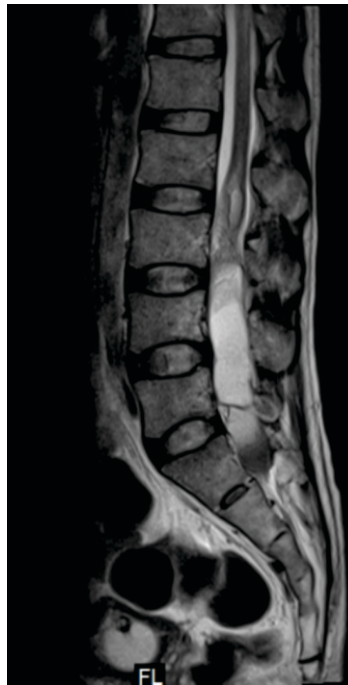

Fig. 2: T2 Mid Sagittal MR Image of the Lumbar Spine Showing Fat in the Solid Component Appearing as Well Defined Hyperintensity in the Upper One Third, Cystic Area Appearing Hyperintense in the Middle One Third and Hemorrhage within the Cystic Component Appearing as Ill-Defined Hypointense Signal

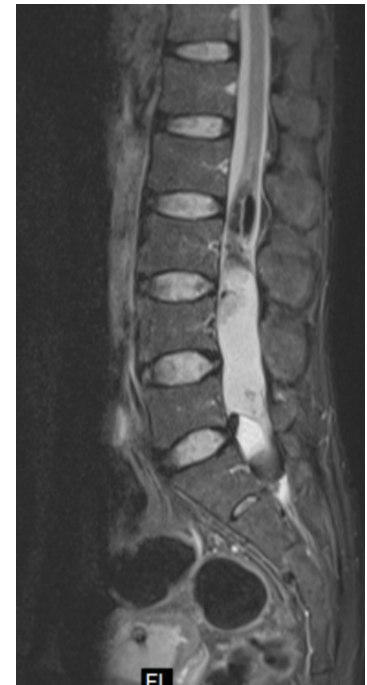

Fig. 3: STIR Mid Sagittal MR Image of Lumbar Spine Showing Suppression of Fat Appearing as Hypointense Signal Predominantly in the Upper One Third, Cystic Component Appearing Hyperintense in the Middle One Third and Hemorrhage Appearing as An Ill Defined Hypointense Signal in the Lower One Third

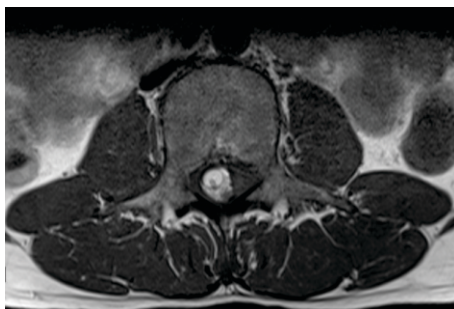

Fig. 4: T1 Axial MR Image through the Upper One Third of the Lesion Showing Hyperintense Fat Signal surrounding the Hypointense Subarachnoid Space

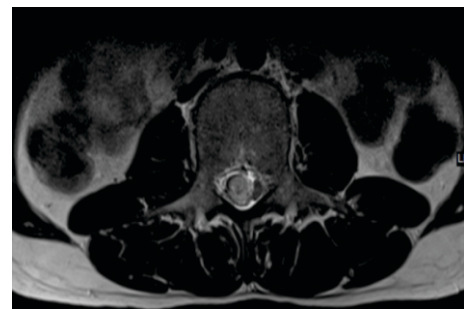

Fig. 5: T2 Axial MR Image through the Upper One Third of the Lesion Showing Hyperintense Fat Signal surrounding the Hyperintense Subarachnoid Space

were confirmed to be due to intralesional calcifications which appeared hyperdense (Fig. 6). The hemorrhagic component seen on MRI was further confirmed on CT scan which showed HU values of 40-60 HU (Fig. 6).

Our patient underwent an excisional biopsy, which confirmed intramedullary dermoid cyst. The tumour could not be resected completely due to its tight adherence to the nerves. Hence the patient is being managed conservatively.

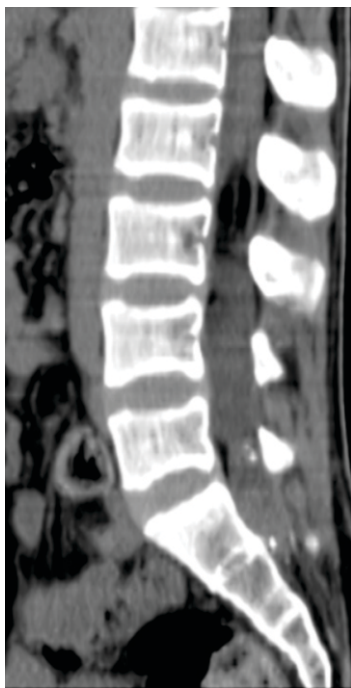

Fig. 6: Mid Sagittal Reconstructed CT Image shows the Hypodense (100 to -110 HU) Fat in the Upper One Third, Cystic Component Appearing Isodense (10 to 15 HU) in the Middle One Third And Hyperdense (40 to 50 HU) in the Lower One Third

Discussion

Dermoids may be congenital or acquired in origin. These tumours constitute 1-2% of intraspinal tumours and are more frequently encountered in children (10-17%) [1]. Congenital lesions are believed to result from inclusion of ectodermal cells during closure of the neural tube in the third to fifth weeks of fetal life. Acquired lesions can result from trauma or surgery. The common

locations of dermoid cyst are scalp, skull bones, intracranial, and intraspinal mainly intradural extramedullary; rarely intramedullary and associated with other spine defects [2].

Intraspinal dermoids occur most frequently in the lumbosacral region (60%), only 5% in the cervical region [3]. Approximately 75% is extramedullary [2].

Clinical Presentation:

Symptoms are generally of late onset and nonspecific, manifesting commonly in childhood often leading to a delay in diagnosis.

Young children and infants often have severe pain, motor regression, weakness. Symptoms depend on the location, extent of the tumour and are a result of the space-occupying lesion causing compression of adjacent structures. Motor disturbances, pain, sensory disturbances, and urologic dysfunction frequently occur [4-6].

Dermoid cysts usually present themselves in childhood. However, in this case, the patient had no associated developmental anomaly of the spine and thus the patient presented at a later age after he had developed significant symptoms.

A dermoid cyst can rupture during surgery, after a trauma, or spontaneously. This can lead to spread of contents along the subarachnoid space and ventricles causing aseptic chemical meningitis [7].

Imaging Diagnosis:

Radiography: Vertebral erosion, spinal canal widening.

MRI: The signal intensity characteristics are variable, depending on the cystic contents. The two major components of fluid and fat are appearing hyperintense on T-1 weighted images being most consistent with the similar findings mentioned by Do-Dai DD *et al* [8]. Areas of hyperintensity are reflecting secretions of sebaceous glands and liquid lipid metabolites. Solid portions

of the tumour are slightly hypointense to isointense compared with spinal cord. On T2-weighted images, the areas of T1 hyperintensity demonstrate relatively decreased signal intensity and the solid portions of the tumour are heterogeneously hyperintense.

Rupture of a dermoid may result in free T1-hyperintense fat drops within the intracranial and intraspinal subarachnoid space [6]. Fat droplets may also rarely be seen within a dilated central canal of the spinal cord as it was reported by De Maio PN *et al* [6].

The differential diagnosis of spinal dermoid cysts includes spinal lipomas, epidermoid cyst and myxopapillary ependymoma.

MR distinguishes dermoid from lipoma by virtue of the non fatty component in the former.

Fat hyperintensity is most specific for dermoid which is not seen in ependymomas and epidermoids. Also intrinsic T1 shortening permits differentiation of dermoid from epidermoid [6].

CT Scan: Tumoural calcifications and fat hypodensity within a dermoid is more easily detected by CT [6].

Diagnosis and Treatment: Although a diagnosis cannot be made without a tissue sample, certain neuroimaging findings are characteristic and useful in helping to distinguish inclusion cysts from other more common spinal lesions. MRI is the modality of choice for diagnosis of dermoid tumours [9].

In addition, radical removal is, at times, precluded by the risk of neurological deficit in cases where tumour capsule adheres tightly to nervous tissue.

Conclusion:

The intramedullary location of a primary dermoid cyst involving the conus as well as cauda equina in an adult is rare and thus makes this case a very unique and rare entity. MRI is the best imaging tool for the diagnosis. CT plays an important complementary role in identifying areas of fat and calcification.

References:

1. Rapoport RJ, Flanders AE, Tartaglino LM. Intradural extramedullary causes of myelopathy. *Semin Ultrasound CTMR* 1994; 15(3):189-225.
2. Altay H, Kitiş O, Calli C, Yünter N. A spinal dermoid tumor that ruptured into the subarachnoid space and syrinx cavity. *Diagn Interv Radiol* 2006; 12(4):171-173.
3. Cha JG, Paik SH, Park JS, Park SJ, Kim DH, Lee HK. Ruptured spinal dermoid cyst with disseminated intracranial fat droplets. *Br J Radiol* 2006; 79(938):167-169.
4. van Aalst J, Hoekstra F, Beuls EA, Cornips EM, Weber JW, Sival DA, Creyten DH, Vles JS. Intraspinal dermoid and epidermoid tumors: report of 18 cases and reappraisal of the literature. *Pediatr Neurosurg* 2009; 45(4):281-290.
5. KrishnaKK, Agarwal PA, Agarwal SI, Jain MM. Dermoid of the conus medullaris. *J Clin Neurosci* 2004; 11(7):796-797.
6. De Maio PN, Mikulis DJ, Kiehl TR, Guha A. AIRP best cases in radiologic-pathologic correlation: Spinal conus dermoid cyst with lipid dissemination. *Radiographics* 2012; 32(4):1215-1221.
7. Sharma M, Mally R, Velho V. Ruptured Conus Medullaris Dermoid Cyst with Fat Droplets in the Central Canal. *Asian Spine J* 2013; 7(1):50-54.
8. Do-Dai DD, Brooks MK, Goldkamp A, Erbay S, Bhadelia RA. Magnetic resonance imaging of intramedullary spinal cord lesions: a pictorial review. *Curr Probl Diagn Radiol* 2010; 39(4):160-185.
9. Calabro F, Capellini C, Jinkins JR. Rupture of spinal dermoid tumors with spread of fatty droplets in the cerebrospinal fluid pathways. *Neuroradiology* 2000; 42(8):572-579.

*Author for Correspondence: Dr. Aditi Gujarathi, Department of Radio-diagnosis, D. Y. Patil Medical College, Hospital and Research Centre, Pimpri, Pune. Cell: 9822429444, Email: aditidoc89@gmail.com